Scapula

Part 1

(lateral view)

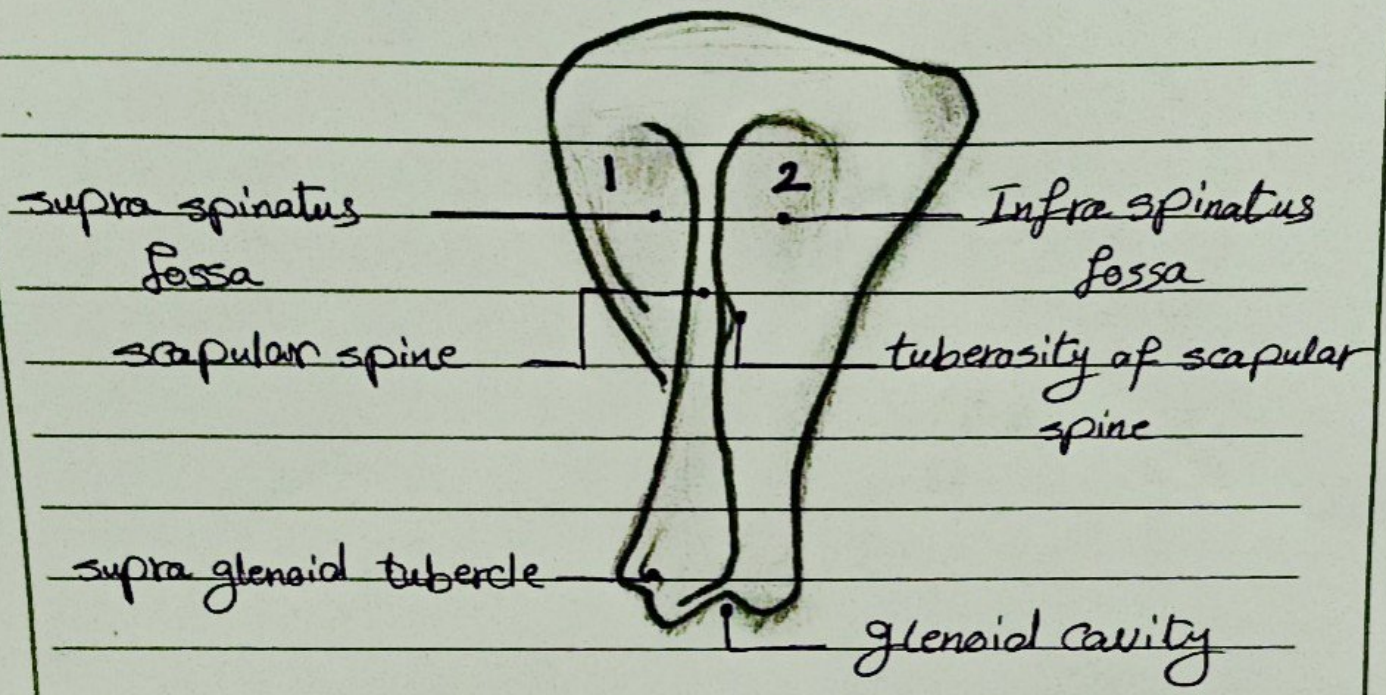

(medial view)

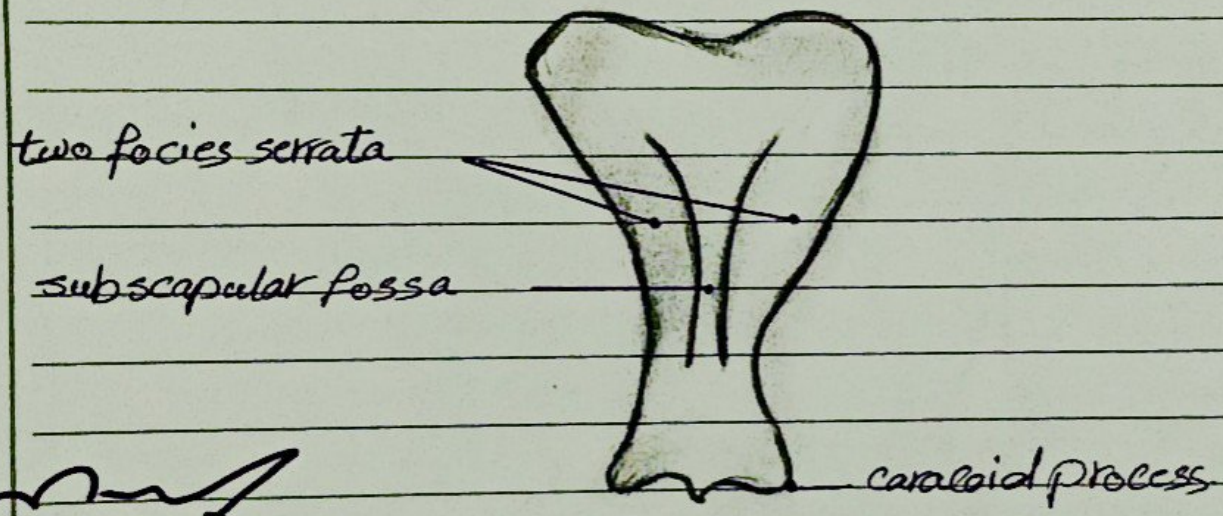

note

1. Acromion process exists in camel, ox, dog and sheep except horse
2. scapula of camel and dog has convex apex

INK MASTERS

خاص لدي مكتبة الفتح

(3:1)

ox

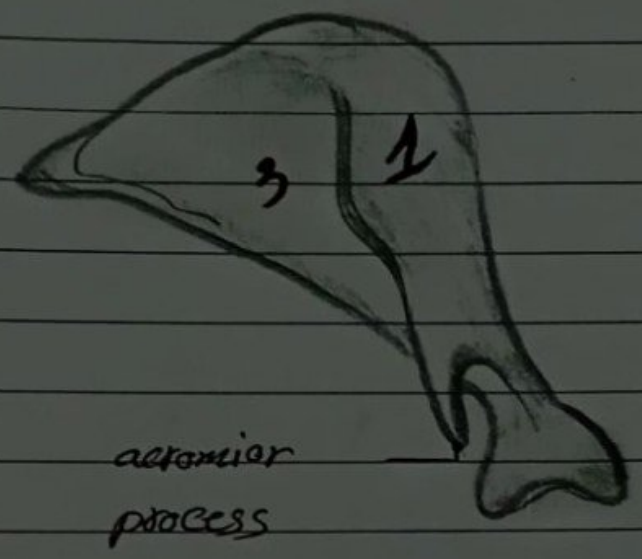

Camel

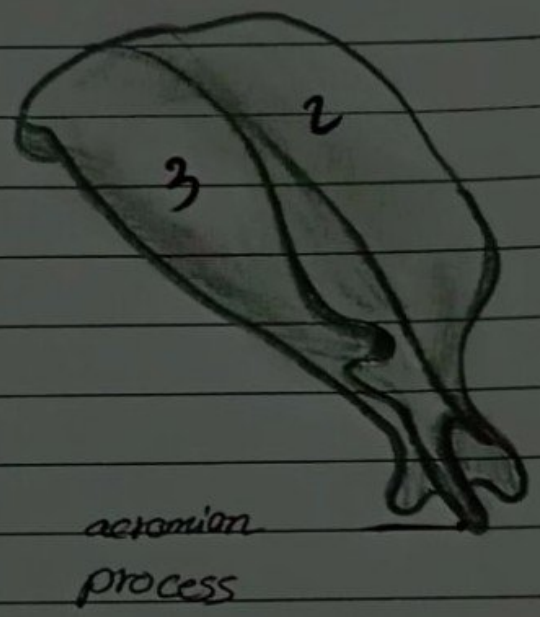

sheep



dog



INK MASTERS

خاص لدي مكتبة الفتح

② humerus

(cranial view)

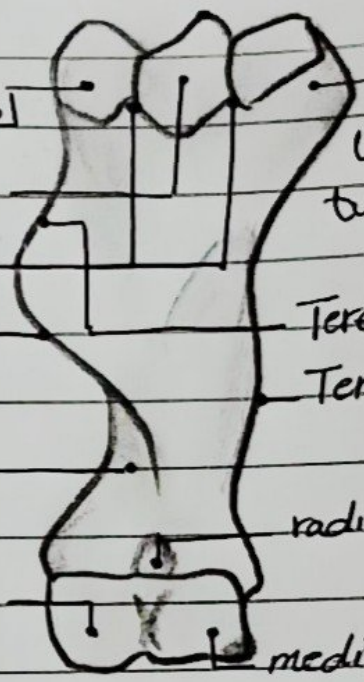

(coudal view)



INK MASTERS
خاص لدي مكتبة الفتح

Camel



no neck
greater tubercle
not divided.

ox and sheep



neck ✓
greater tubercle
divided ✓



Radius & ulna

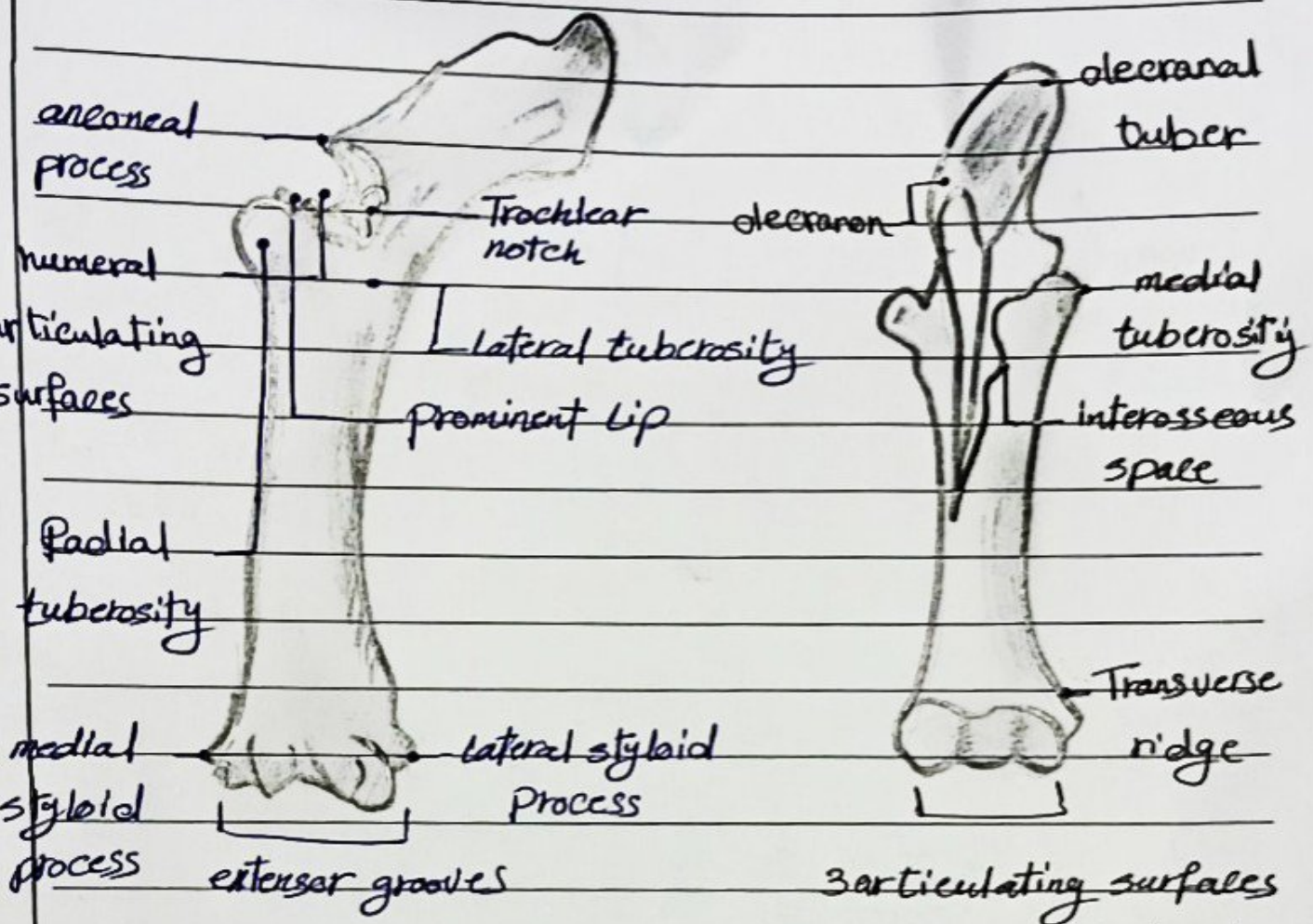

*The defferences of horse and othe species

1- horses . has one intrasseous space
. ulna is partially fused with radius up $\frac{2}{3}$ of the bone

2- cattle (ox, sheep) . has Two interosseous spaces.
. ulna extends till the end forming styloid process

3- camel . has interosseous foramen
. ulna is completely fused with radius.

4- dog . Radius and ulna are two separated bone
* like human.

خاص لدي مكتبة الفتح

⑨ carpus

8 short bone arranged in proximal & distal rows

I. Proximal row

1. Radial carbal bone 2. Intermediate carbal bone
3. ulnar carpal bone 4. Accessary carpal bone

1. Radial carpal bone → شبه كرسي الانزيه
2. Intermediate carpal bone → شبه كرسي العجلة
3. ulnar carpal bone → it's The smallest one أصغر واحدة فيهم
4. accessary carpal bone → discoid in shaped, more flattened and like PBCs يبقى شبه القرص وبططة شبه كرات بدم الحمراء

II distal row

1. first carpal 2. second carpal
3. Third carpal 4. fourth carpal

In horse: 7 or 8 carpal bone
In sheep: has 6, 1st absent, 2nd, 3rd are fused الأولى مش موجودة والباقي الثانية ملحومين
camel: has 7, 1st absent
dog: has 7, radial + Intermediate: عظمة واحدة (ملحومين بعض)

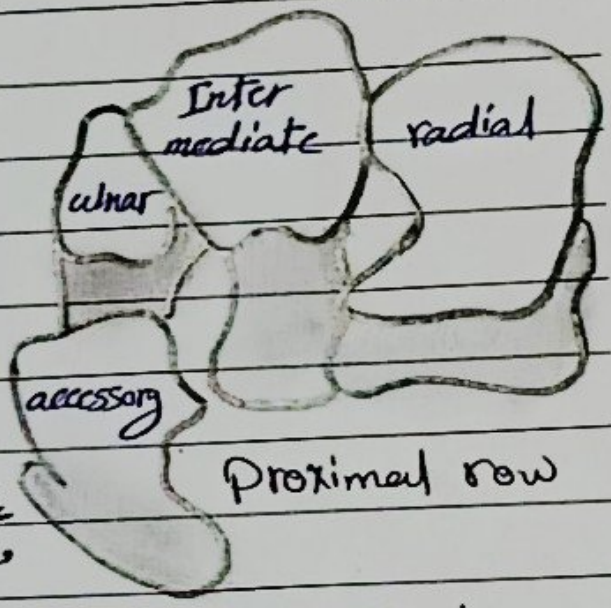

Proximal row

1st → it's small one
2nd → small and irregular horispherical shape شكل نصف كرة منتظم
3rd → The largest bone ويبقى شبه الفط
4th → wedge-shape شبه كرسي العجلة

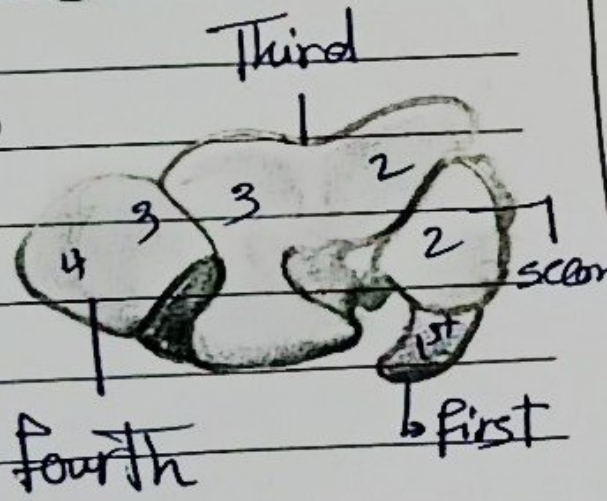

خاص لدي مكتبة الفتح
INK MASTERS

muscles of fore limp



INK MASTERS
خاص لدي مكتبة الفتح

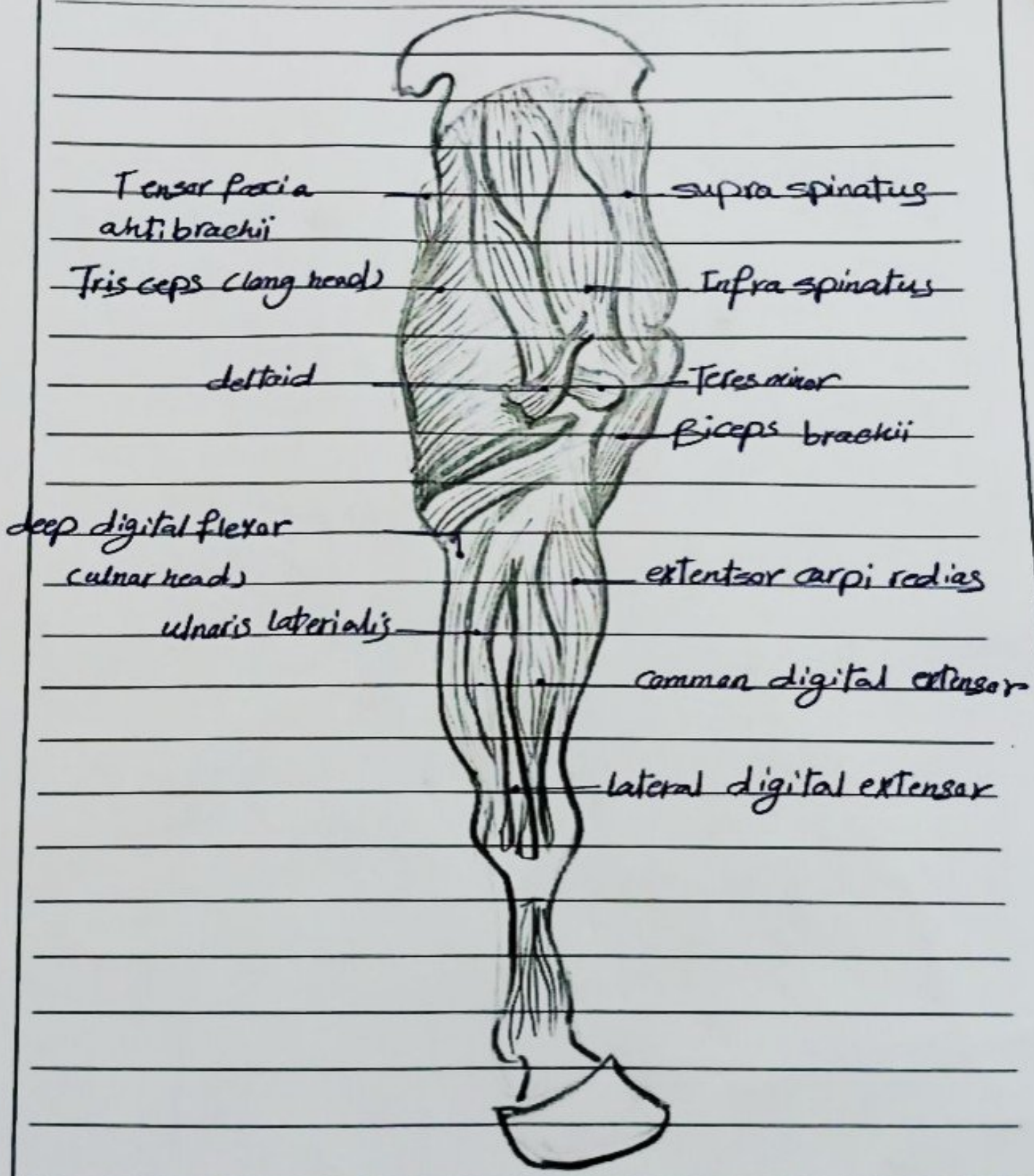

INK MASTERS

خاص لدي مكتبة الفتح

1- axillary artery

2- supra scapular artery

3- subscapular artery

4- c.d circumflex humeral

5- Thoraco dorsal artery

6- brachial artery

7- deep brachial artery

8- collateral ulnar artery

9- common interosseous artery

10- median artery

11- radial artery

12- lateral palmar artery

13- medial palmar artery

14- lateral palmaar proper digital artery

15- medial palmar proper digital artery

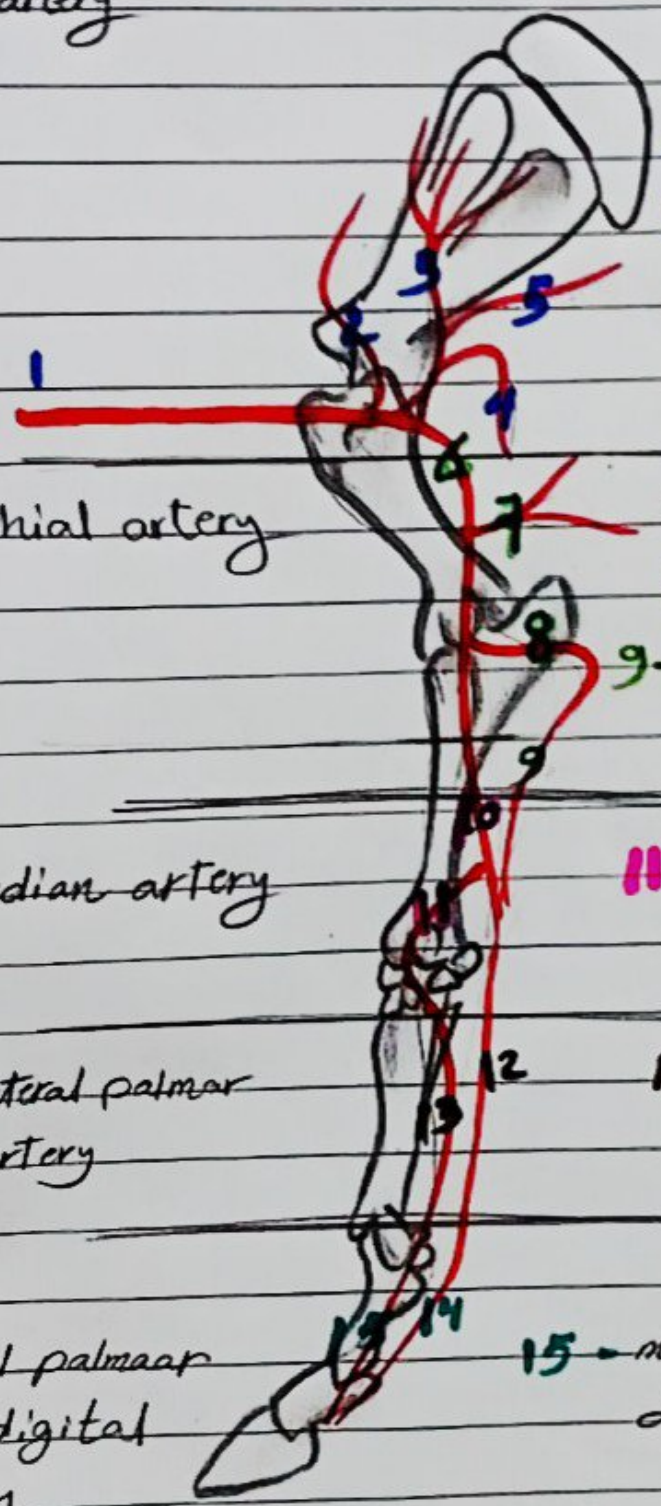

بيعلي على بن قبله

INK MASTERS

خاص لدي مكتبة الفتح

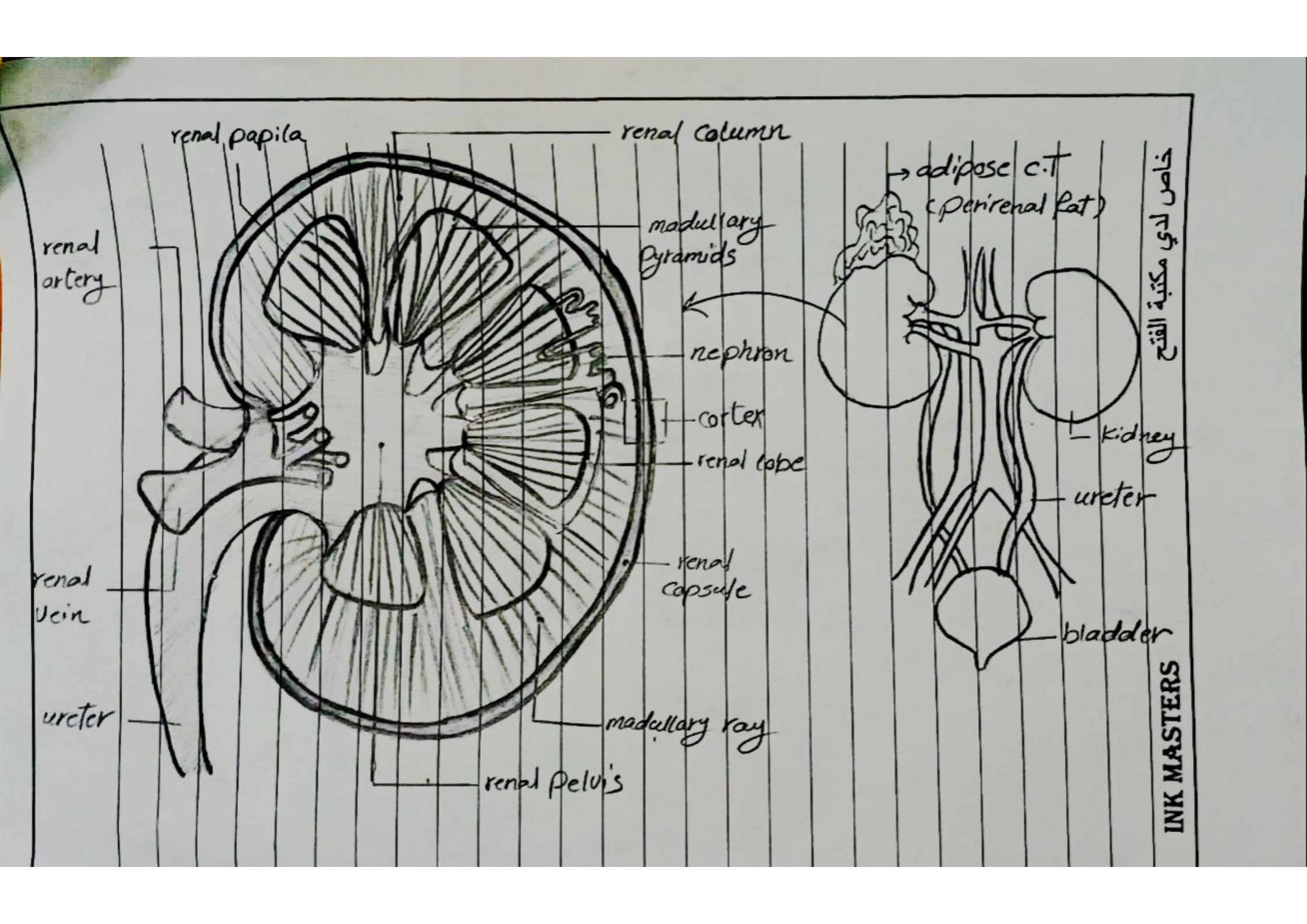
renal papila
renal column
renal artery
medullary pyramids
nephron
cortex
renal lobe
renal capsule
renal vein
ureter
medullary ray
renal pelvis
adipose c.T
(perirenal fat)
kidney
ureter
bladder
خاص لدي مكتبة الفتح
INK MASTERS

smooth kidney



fissured kidney



in large ruminant

in all animals except large ruminant

bear shape



right kidney of horse

very important ^-

kidney of camel ←

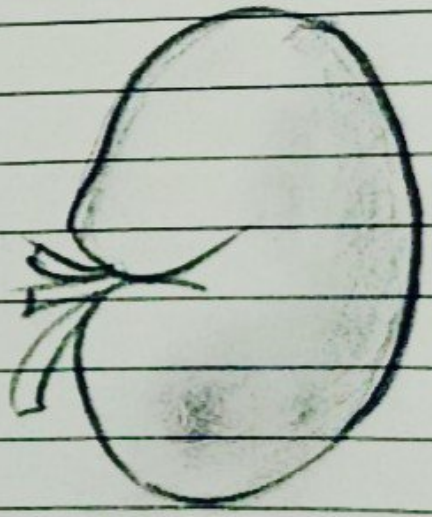

left kidney of horse

وكان الله بالسر عليم

bean shape

INK MASTERS

خاص لدي مكتبة الفتح

female genital sys

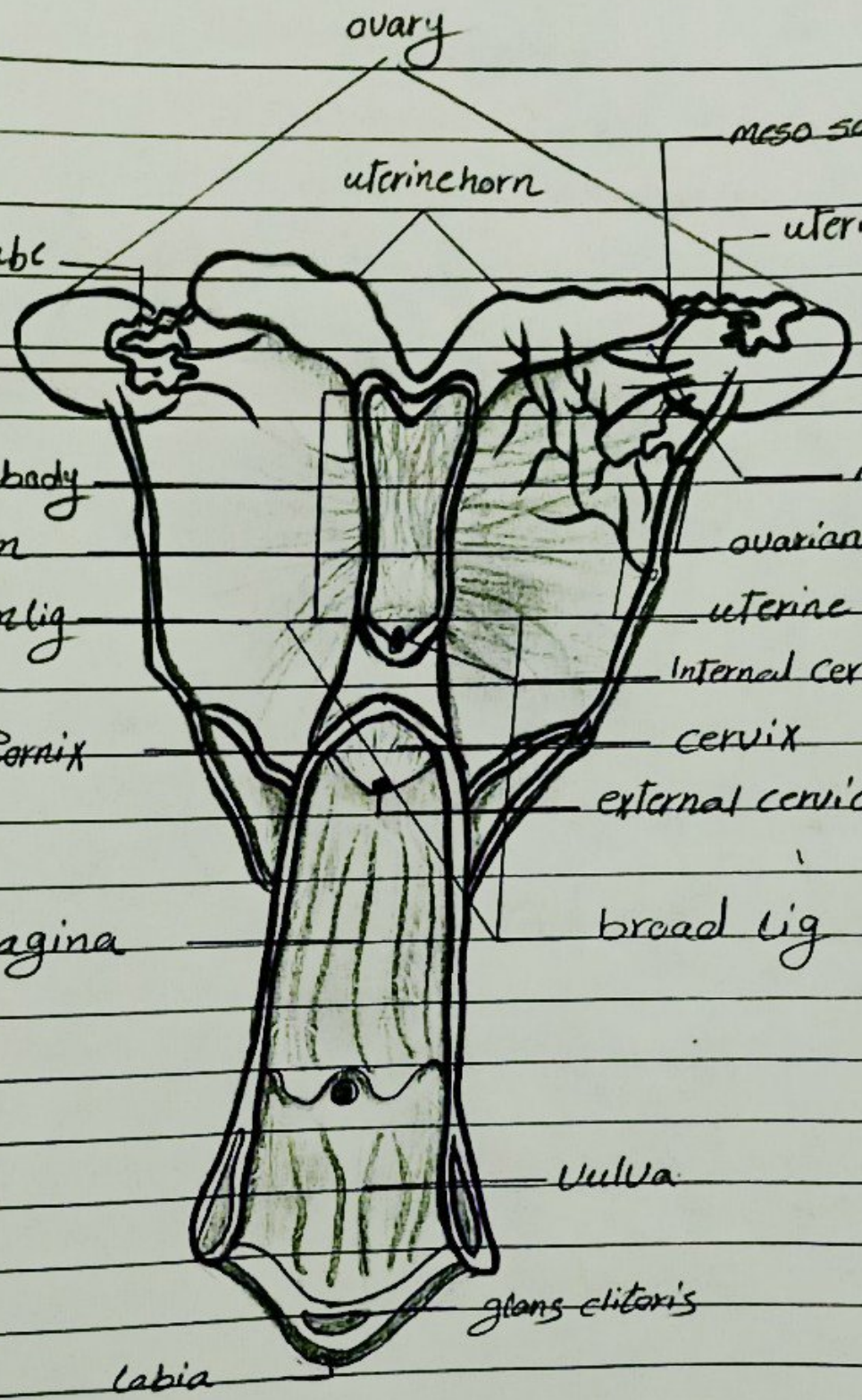

تمرين الذي هزانا هذا ♡

سبرين علي ♡

INK MASTERS
خاص لدي مكتبة الفتح

Oogenisis

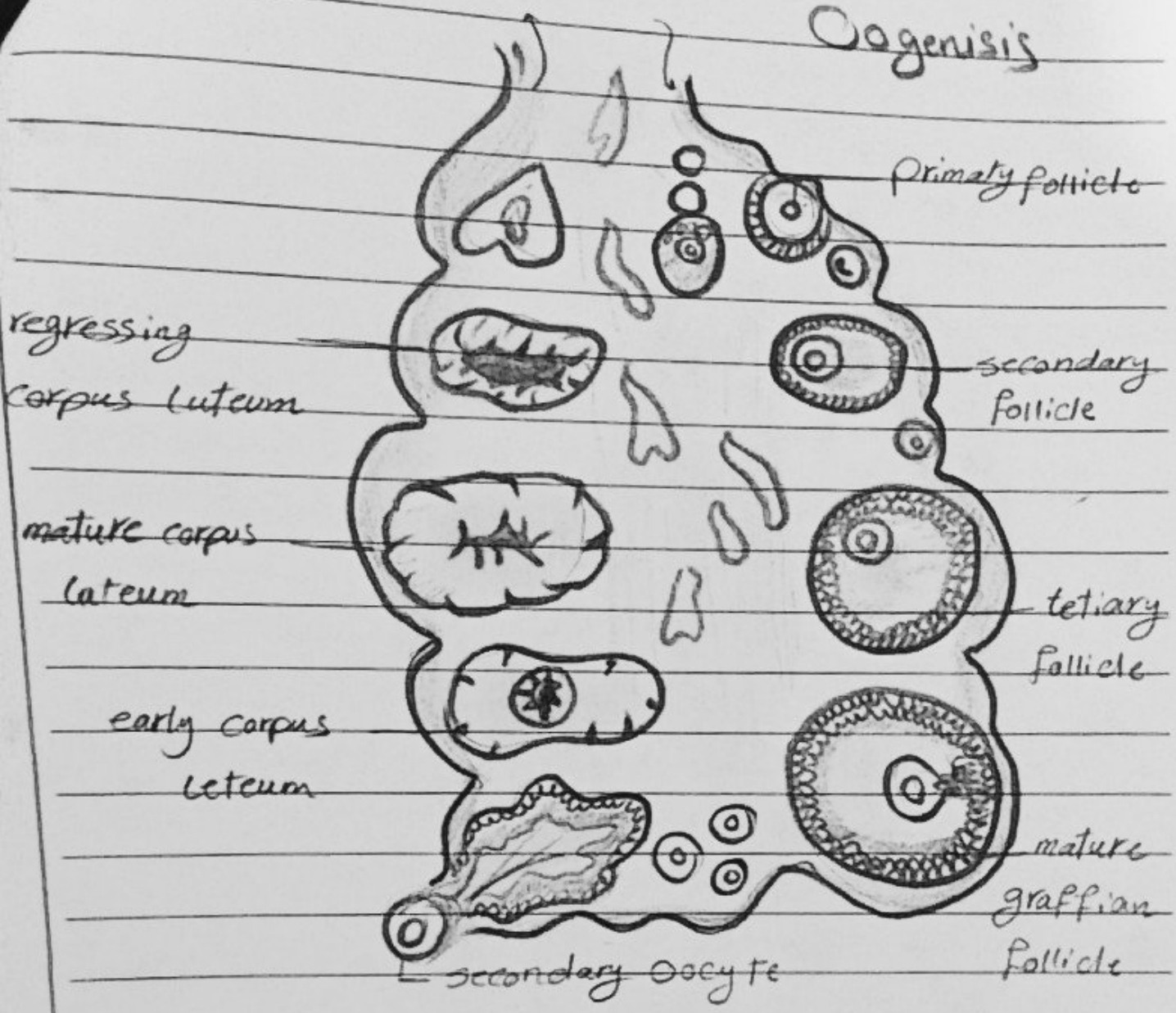



INK MASTERS
خاص لدي مكتبة الفتح

male genital system

reproductive organs of the Bull and Ram except glans penis and shape of testis

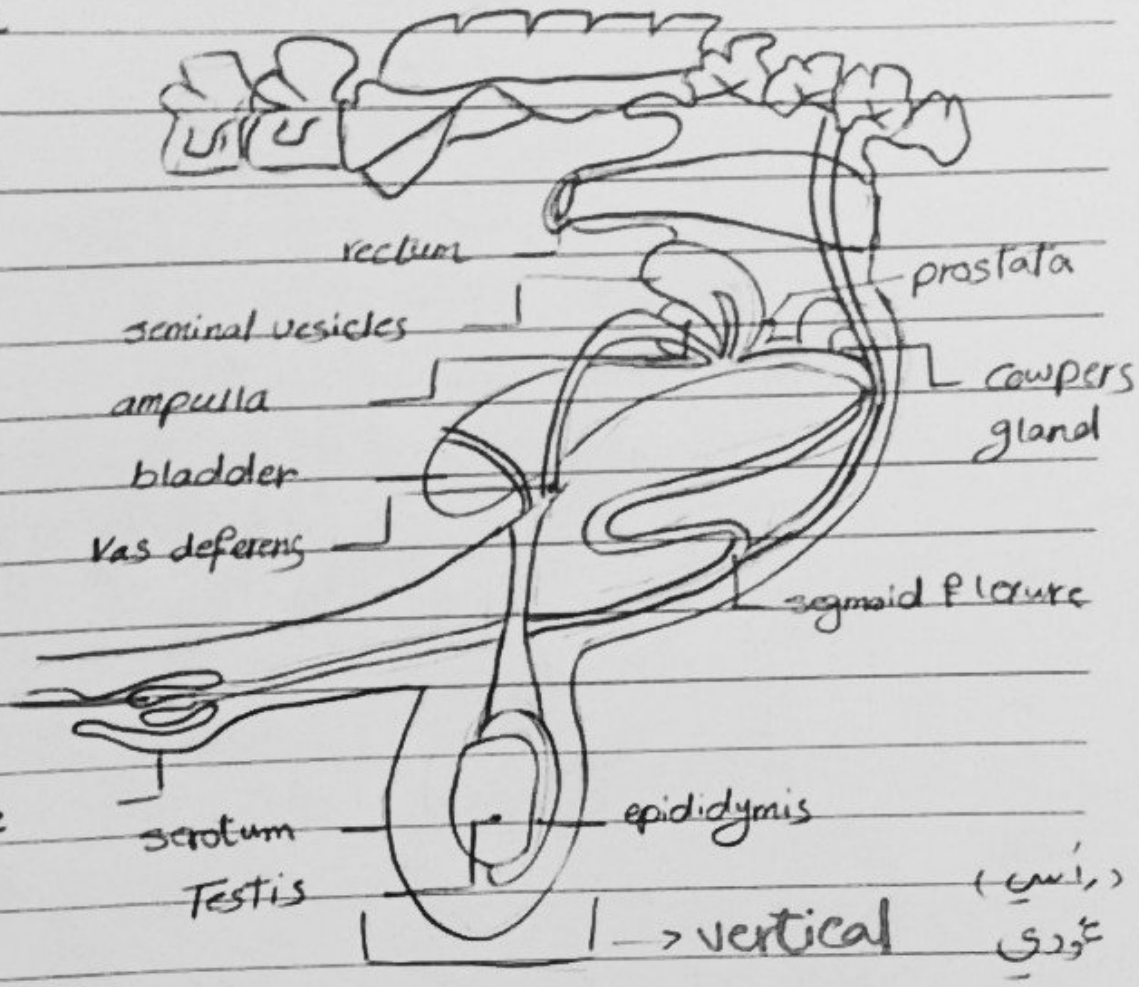

reproductive organs of stallion

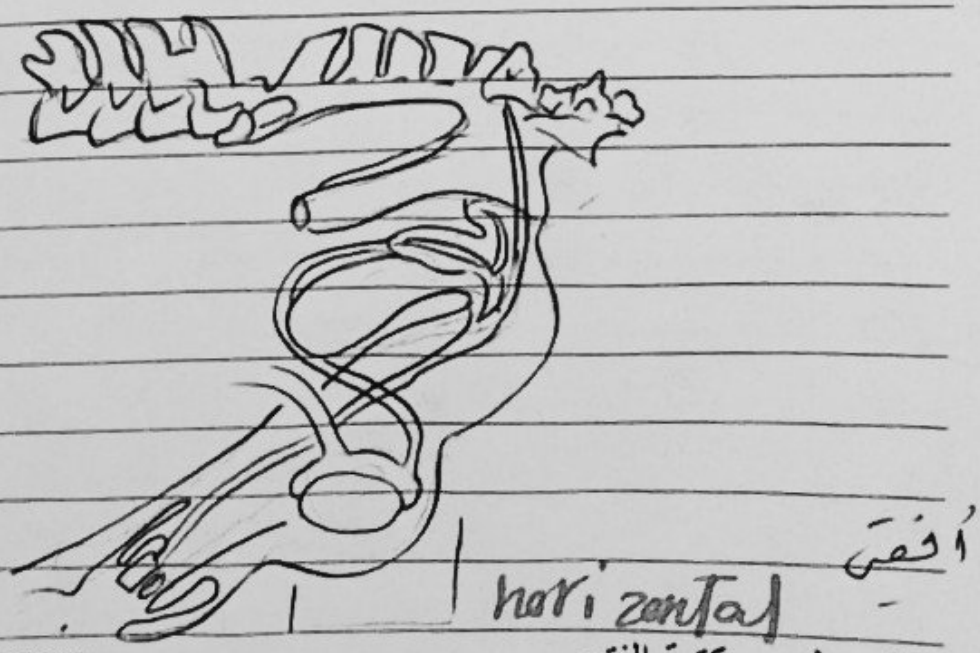

INK MASTERS
خاص لدي مكتبة الفتح

by| 3ogbd

structure of scrotum.

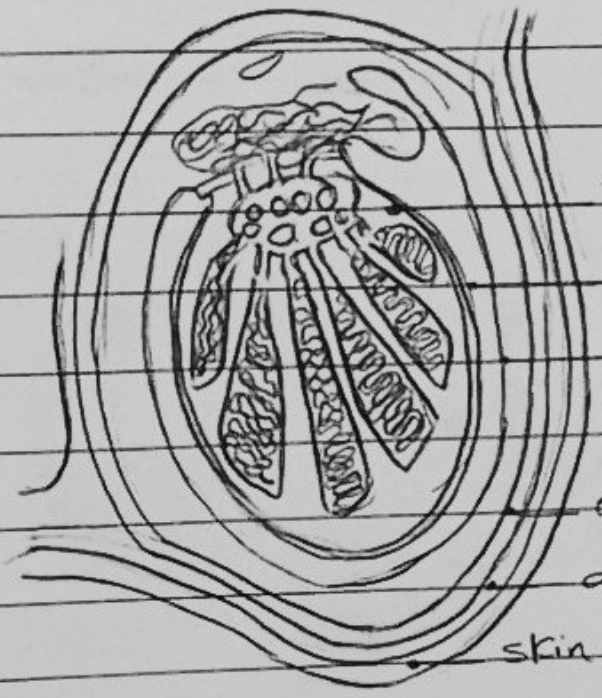

structure of testis

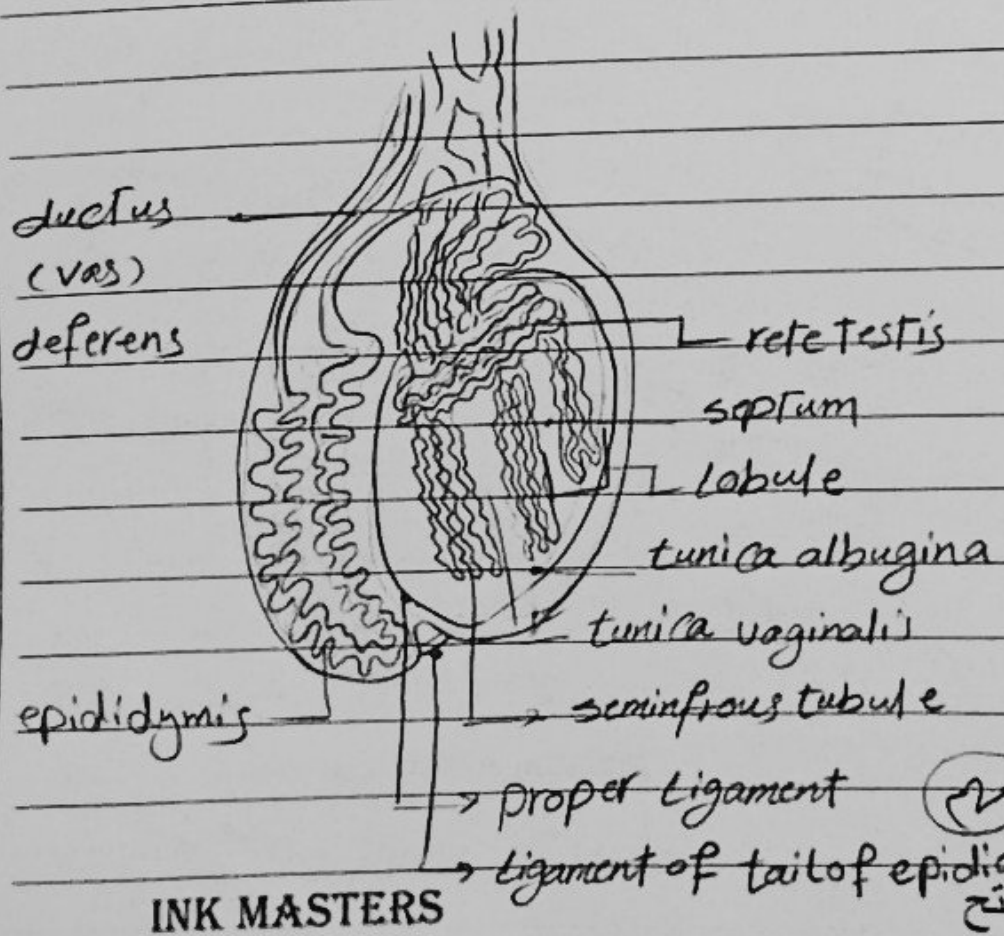

INK MASTERS
خاص لدي مكتبة الفتح

testis in diff spicies

in Bull

verticle

clear blood vessels

in ram

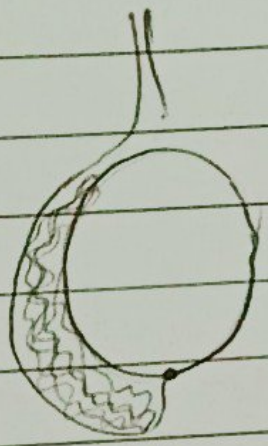

verticle

in stallion

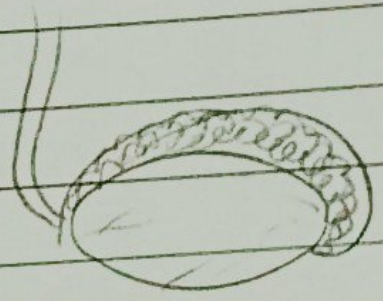

horizontal

② penis in diff species

stallion

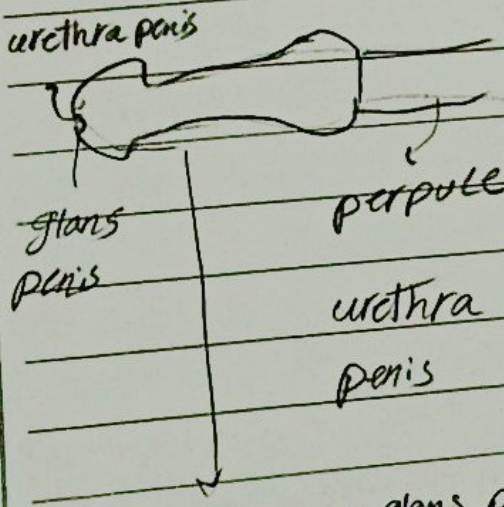

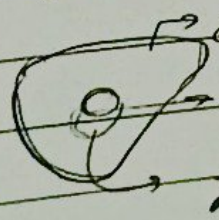

Bull





Ram

خاص لدي مكتبة الفتح